J Microbiol Immunol Infect
2005;38:183-188

Clinical management and outcome of childhood lung abscess: a 16-year experience

Pei-Chun Chan, Li-Min Huang, Ping-Sheng Wu, Po-Young Chang, Tsao-Ton Yang, Chun-Yi Lu, Ping-Ing Lee, Jung-Min Chen, Chin-Yun Lee, Luan-Yin Chang

Department of Pediatrics, National Taiwan University Hospital, College of Medicine, National Taiwan University, Taipei, Taiwan

Received: June 15, 2004 Revised: October 25, 2004 Accepted: December 2, 2004

In order to evaluate the clinical manifestations, management and outcome of childhood lung abscess, a retrospective chart review of 27 pediatric patients with International Classification of Diseases, Ninth Revision-Clinical Modification (ICD-9 CM) code of 503.1 (lung abscess) from August 1987 to August 2003 was conducted. Among the 27 patients (14 males and 13 females), 30% (8/27) were primary lung abscess and 70% (19/27) had underlying chronic diseases (secondary lung abscess). The predisposing factors of the primary group (n = 8) included 6 cases of respiratory tract infection, 1 with choking during swimming, and 1 with laceration wound. The underlying diseases in the secondary group (n = 19) included 10 cases of hematologic disorder (52%), 3 of congenital heart disease, 2 of central nervous system anomalies, and 1 each of hyperimmunoglobulin E syndrome, chronic lung disease, liver cirrhosis with fistula formation, and Swyer-James syndrome. Eleven patients (41%) underwent diagnostic tapping, including echo-guided aspiration (10 cases) and computed tomography-guided percutaneous needle aspiration (1 case). Positive yield rate from aspiration of lung abscess was 63.6% (7/11). Surgical intervention was performed in 8 (42%) of the secondary group and in 1 patient from the primary group. The pathogens were identified in 11 patients (41%): 5 with oral flora, 2 with *Staphylococcus aureus* plus other pathogens, 1 with *S. aureus* alone, 1 with *Pseudomonas aeruginosa* plus *Proteus mirabilis*, 1 with *P. aeruginosa* alone, and 1 with *Aspergillus*. The average duration of parenteral antibiotic use was 40 days. Five cases (18.5%) died due to poor control of the underlying diseases, and 4 of the patients (15%) had sequelae (2 with bronchiectasis and 2 with lung fibrosis). Seventy percent of lung abscess occurred in children with underlying medical conditions. Early percutaneous aspiration has an important role in identification of pathogens. Oral anaerobes and *S. aureus* are the core pathogens in primary lung abscess and Gram-negative pathogens should also be considered in secondary lung abscess.

Key words: Bacterial infections, lung abscess, pathogens, retrospective studies, risk factors

Lung abscesses are thick-walled cavities that contain purulent material and result from pulmonary infection. The infection has led to suppurative necrosis and destruction of the involved lung parenchyma [1]. Lung abscess, defined as a circumscribed area of necrosis 2 cm or greater in size, occurs within an area of pre-existing aspiration pneumonia in a dependent section of the lungs, although lung abscess can also form in areas of pre-existing infection or from hematogenous spread [2]. Some authors emphasized image-guided aspiration before antibiotics use in children in order to identify the pathogen [3,4]. Aspiration was also subsequently suggested in adults [5,6]. As in previous literature, lung abscesses are classified into 2 groups: primary lung abscess develops from those without underlying disease while secondary lung abscess develops from those with underlying medical conditions, such as illnesses related to aspiration, immunocompromised states, and metastatic or systemic infections [7-10].

Information on primary childhood lung abscess is limited. We reviewed cases of lung abscess in a single medical center, in order to better understand the clinical manifestations, management, and outcomes of childhood lung abscess.

Materials and Methods

Between August 1987 and August 2003, a total of 58 pediatric patients with age ≤18 years old were discharged with the code number of lung abscess (International Classification of Diseases, Ninth Revision-Clinical

Corresponding author: Luan-Yin Chang, M.D., Department of Pediatrics, National Taiwan University Hospital, 7F, No. 7, Chung-Shan South Road, Taipei 100, Taiwan.
E-mail: ly7077@tpts6.seed.net.tw

Modification [ICD-9 CM] code 503.1) from the National Taiwan University Hospital in Taipei, Taiwan. After reviewing their charts, chest radiography, and computed tomography (CT), 27 were enrolled into this study while the other 31 patients with empyema or necrotizing pneumonia were excluded. Lung abscess was defined as a solitary or dominant cavity that measured at least 2 cm in diameter [2,11], and a collection of pus in the lung with an air-fluid level and a reactive rim on chest radiography or CT.

We recorded the demographic characteristics, clinical manifestations, time of defervescence, time of largest size of abscess, and time of abscess diminishment. We also reviewed their chest X-ray findings, including the location of the abscess, pneumothorax, pleural effusion, small cavity (2-4 cm in diameter), large cavity (≥4 cm), pneumatocele, and spherical mass.

Laboratory data, including white blood cell count, platelet count, and C-reactive protein on admission, and the results of smears and cultures from blood, pus or aspiration material were recorded and analysis. Variables compared included time between admission and aspiration, surgical intervention, total duration of parenteral antibiotics use, total course of antibiotics, outcome, and sequelae.

Student's *t* test or chi-squared or Fisher exact test were used for statistical analysis (SPSS Version 10.0; SPSS Inc., IL, USA). We also compared cases of the primary group with the secondary group, uncomplicated cases with complicated cases, and survival cases with fatal cases.

Results

Demography and associated conditions

A total of 27 patients were enrolled in this study, 14 boys and 13 girls. The underlying conditions of 19 patients (70%) in the secondary group were leukemia (8/19, 42%), congenital heart disease (3/19, 16%), central nervous system anomalies (2/19, 11%), and 1 case each of aplastic anemia, Fanconi anemia, hyperimmunoglobulin E (hyper-IgE) syndrome, Swyer-James syndrome, chronic lung disease, and liver cirrhosis with fistula formation. Hematologic diseases were the most common underlying diseases encountered, followed by congenital heart diseases.

Predisposing factors

Predisposing conditions are listed in Table 1 and divided into 2 groups according to the underlying medical conditions (primary and secondary group). Upper respiratory tract infection was the leading condition of the primary group (6/8, 75%). One week before fever onset, a previously healthy 3-year-old girl had mildly choked during swimming. Chest X-ray and CT scan showed a lung abscess over the left upper lung field on the fourth day of fever (Fig. 1A, 1B, 1C). One 14-year-old boy had an abrasion wound over the right ankle 14 days before *Staphylococcus aureus* lung abscess occurred. In the secondary group, immunocompromised status was the leading predisposing condition (14/19, 73.7%).

Table 1. Predisposing conditions for childhood lung abscess

Predisposing condition	No. of patients
Primary[a] (n = 8)	
Upper respiratory infection symptoms	6
Choking during swimming	1
Nursing student	1
Laceration wound	1
Secondary[b] (n = 19)	
Immunocompromised	14
Frequent previous pneumonia	4
Upper respiratory infection symptoms	3
Bedridden	1
Choking	2

[a]One patient in the primary group had 2 predisposing conditions.
[b]Four patients in the secondary group had at least 2 predisposing conditions.

Clinical manifestations

Table 2 shows the initial symptoms. All of these patients had fever (100%), 66.7% (18/27) had cough, 22.2% experienced chest pain or discomfort, and 18.5% presented with dyspnea. Body weight loss and decreased appetite were noted in 3.7% and 11%, respectively. The locations for each abscess are shown on Table 3. Right upper lung was the most frequently involved area (28.6%), followed by multiple lobar involvement and left lower lobe involvement (22% each). Fifty two percent of the lung abscess were greater than 4 cm in size.

Diagnostic and surgical procedures

Nine patients (33%) underwent echo-guided needle aspiration of the lung abscess, 1 underwent CT-guided aspiration, and 1 underwent echo-guided central venous pressure (CVP) tube drainage. Three needed lobectomy later. Chest tube insertion for better drainage was later performed in the operation room for the one who underwent CVP tube drainage first. Two patients

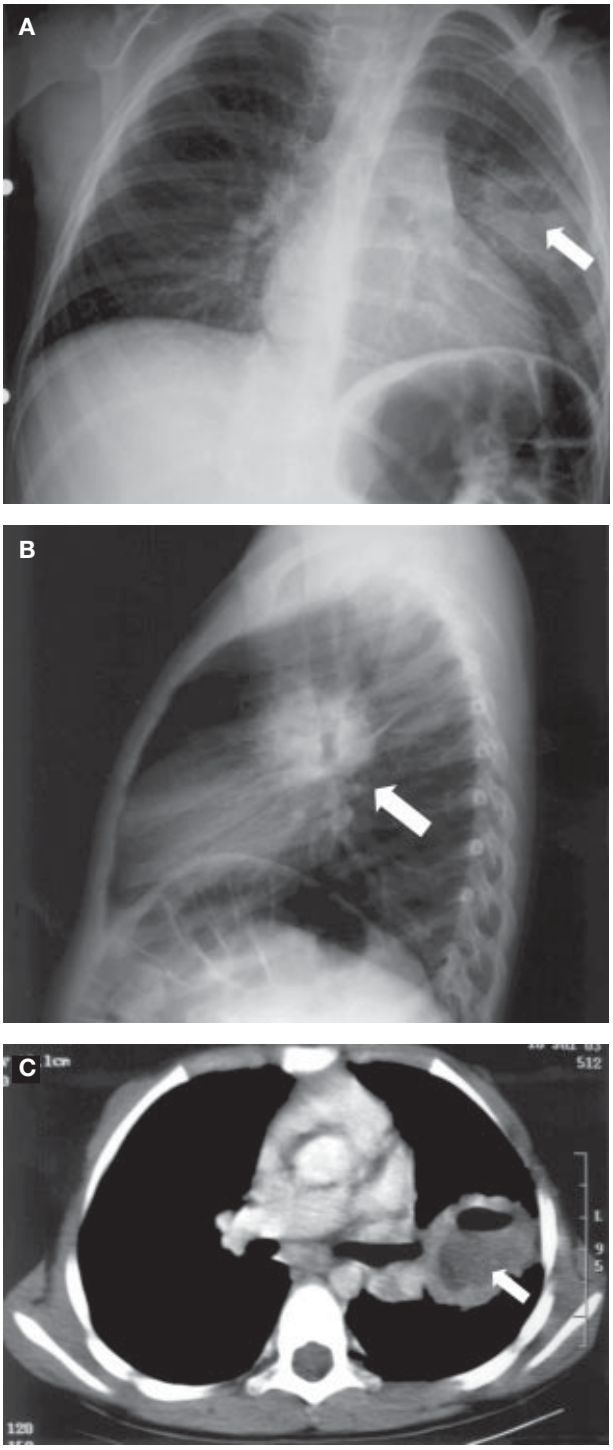

Fig. 1. Lung abscess of a 3-year-old girl who went swimming and had minor choking 1 week before the onset of fever: a spherical mass with air-fluid level was found over left upper lobe (arrows) at emergency room after fever for 3 days with upper airway symptoms: (A) Left upper lobe abscess over posterior-anterior view and (B) lateral view of chest radiography. (C) Computed tomography revealed left upper lobe abscess formation without massive consolidation or pleural effusion. There was neither mass lesion nor cystic lesion.

underwent lobectomy only without preceding aspiration of their lung abscess. A total of 5 patients (18.5%) underwent lobectomy, 1 with right lower lobe, 3 with right middle lobe (RML), and 1 with right upper lobe plus RML.

Two patients with underlying complex congenital heart diseases underwent surgery for the removal of vegetation in one without aspiration and the removal of seroma around a previous shunt in the other. Both of these patients had pathogens identified by blood culture (viridans group streptococci in one and *Enterococcus faecium* and methicillin-resistant *S. aureus* [MRSA] in the other), and not by surgical tissue culture. One patient with a right ankle abrasion wound in the primary group developed multiple lung lesions later. Pus from the wound yielded staphylococci and *Eubacterium* from the referring hospital and later, the curettage from bone fenestration of the left femur and right fibula yieled *S. aureus* (this was also the only patient in the primary group who underwent surgical intervention). Surgical interventions were performed in 8 patients (42%) in the secondary group.

Pathogens of lung abscess

The isolation rate from abscesses was 63.6% (7/11) and oral flora were the most common in this series. Single pathogen was isolated in 6 specimens: MRSA, viridans group streptococci, *Eikenella corrodens*, group G streptococcus, *Pseudomonas aeruginosa* and *Aspergillus.* Mixed infection of *Escherichia coli, S. salivarius,* and group F streptococci was found in 1 specimen.

Table 2. Clinical manifestations of lung abscess in children

Presentation	No. of patients (%) n = 27
Fever	27 (100)
Cough	18 (66.7)
Rhinorrhea	6 (22.2)
Chest pain	6 (22.2)
Dyspnea	5 (18.5)
Headache	3 (11.1)
Decreased appetite	3 (11.1)
Lethargy	3 (11.1)
Body weight loss	3 (11.1)
Vomiting	1 (3.7)
Diarrhea	1 (3.7)
Sore throat	1 (3.7)
Dizziness	1 (3.7)
Generalized edema	1 (3.7)
Shock	1 (3.7)
Hoarseness	1 (3.7)
Chills	1 (3.7)

Table 3. Abscess location and size

	No. of patients (%) n = 27
Location	
Right upper lobe	8 (29.6)
Multi-lobar (≥2)	6 (22.2)
Left lower lobe	6 (22.2)
Right lower lobe	4 (14.8)
Left upper lobe	2 (7.4)
Right middle lobe	1 (3.7)
Size[a]	
≥4 cm	14 (51.9)
<4 cm	12 (44.4)

[a]The size of 1 case could not be measured.

Treatment course

Twelve patients (44%) needed intensive care, 9 (33%) needed ventilator support, and 15 (55%) needed oxygenation. The average duration of hospitalization was 44.0 ± 30.6 days. The mortality rate was 18.5% and 4 of the survivors (14.8%) had sequelae. The average duration of antibiotic use was 40 ± 27.4 days (range, 7-101 days). Of these, 60% needed antibiotic therapy longer than 36 days and only 15.8% received antibiotics shorter than 21 days.

The average interval from admission to defeverence was 15.5 ± 20.0 days. Among the patients that underwent aspiration, 6 patients (6/11, 55%) achieved afebrile status before aspiration and they were all in the secondary group. In those who became afebrile after aspiration (4/11), the mean duration from aspiration to defeverence was 7.3 days (range, 3-10 days). The mean duration from the date of defeverence to the date of abscess disappearance was 48.6 ± 35.8 days.

Outcomes

The mortality rate was 18.5% (5/27), all of the 5 children died due to intractable underlying diseases. Eleven patients (41%) had complications, such as respiratory failure (n = 6), pneumothorax (3), shock (1), osteomyelitis (1), and colon perforation (1). Four surviving patients (15%) had sequelae (2 with bronchiectasis and 2 with lung fibrosis).

Comparison between subgroups

In comparison with survivors, the mortalities had longer courses of hospitalization and duration of use of parenteral antibiotics (p=0.023, 0.016). In the secondary group, longer hospitalization was the only significantly different factor compared with the primary group. In comparison with patients of the secondary group, the 8 patients with primary lung abscess had no intubation, no necessity of intensive care, shorter duration of parenteral antibiotic use (27.88 ± 22.83 vs 45.11 ± 28.79 days, p=0.146), less surgical intervention (1 patient [12.5%] vs 8 patients [42%], p=0.201) and aspiration, no mortality, and low unfavorable outcome, although the differences were not statistically significant. The age and even the size of abscesses were similar in these 2 groups.

Patients with unfavorable outcomes (mortality and sequelae) had longer intubation periods and longer intensive care unit stay than patients with favorable outcomes (p=0.045 and 0.037, respectively). Complicated patients tended to be male and have longer oxygen usage, higher referral rate, and higher mortality in this series (p=0.04, 0.018, 0.034, 0.006, respectively) [Table 4].

Discussion

This study revealed that most (70%) of childhood lung abscess cases have underlying medical diseases, and oral flora as well as *S. aureus* are the most common pathogens of childhood lung abscess. Early aspiration may increase the chances of finding the true pathogens.

With recent advances in interventional radiology and diagnostic imaging, percutaneous drainage under echo or CT guidance is a simple and effective method for the diagnosis and management of lung abscess in neonates and children [12-15]. The drainage is not only an effective method of treating refractory lung abscesses, but also obviates major operation [16]. Surgery is reserved for lung abscess with poor response to antibiotic treatment [1], for those with underlying anatomic or physiologic comorbidities [17], and for larger abscesses [18].

In this series, 11 patients underwent aspiration for both diagnostic and therapeutic aims, but 4 of them belonged to the secondary lung abscess group and still needed surgical intervention. In 1 patient, *Aspergillus* was not detected until biopsy was done and he subsequently died despite the provision of antifungal agents and intensive care. Conservative treatment is favored for children, especially in the primary group. However, the necessity of early pathogen detection and debridement in the secondary group should be further investigated.

One of our patients who had hyper-IgE syndrome (Job's syndrome) also suffered from lung abscess and characteristic MRSA was isolated from the aspiration of the abscess. A patient with Swyer-James syndrome, a rare disease with a unilateral hyperlucent lung due to

Table 4. Comparative data for patients with uncomplicated and complicated courses

Variable [n (%) or mean ± SD]	Uncomplicated n = 16	Complicated[a] n = 11	*p*
Age (years)	9.82 ± 5.47	8.22 ± 6.47	0.493
Gender (M/F)	5/11	9/2	0.018[c]
Duration of admission (days)	40.5 ± 31.46	49 ± 30	0.489
Duration of intubation (days)	0.5 ± 1.26	5.82 ± 12.46	0.188
Duration of parenteral antibiotics (days)	34.88 ± 25.79	47.45 ± 30.38	0.258
Oxygen use	1.62 ± 2.58	12.91 ± 15.78	0.04[c]
Referral	5/16 (31.3)	8/11 (72.7)	0.034[c]
With ICU stay	5/16 (31.3)	7/11 (63.6)	0.096
Size of abscess ≥4 cm[b]	7/16 (43.8)	7/10 (70.0)	0.191
Abscess aspiration	6/16 (37.5)	4/11 (36.4)	0.952
Total duration of antibiotics ≥28 days	9/16 (56.3)	8/11 (72.7)	0.384
Mortality	0/16 (0)	6/11 (54.5)	0.006[c]

Abbreviations: SD = standard deviation; M = male; F = female; ICU = intensive care unit

[a]Complicated cases included cases with pneumothorax, organ failure/dysfunction (respiratory, hepatic, renal), chronic osteomyelitis, paraplegia and spinal shock due to leukemia relapse, colon perforation.

[b]The size of 1 case could not be measured.

[c]Statistically significant.

bronchiolitis obliterans and pulmonary artery hypoplasia, who experienced recurrent bronchopneumonia and bronchiolitis since 6 months of age, was hospitalized 4 times prior to the onset of the lung abscess. Our patient presented with recurrent lower respiratory infections over bronchiectatic airways, which might have led to lung abscess formation.

Most bacteriology of lung abscess emphasizes the importance of anaerobes, both in adults and children [19-21]. This study had similar findings. In most studies in adults, mixed anaerobic infection is found in 85-93% of cases and exclusive anaerobic infection ranges from 10-77%. However, 1 study claimed that there were no anaerobes isolated in their series [22] and the leading pathogens were *Klebsiella pneumoniae, S. aureus, Haemophilus influenzae* and *S. pneumoniae*. This may be due to the lower availability of specimens from lung abscess in the series and the results of culture based on sputum mostly. Moreover, the percentage of secondary lung abscess varied. Fourteen previous healthy children with lung abscess received antibiotics alone, without invasive procedures, in Montreal Childrens' Hospital, McGill University [8]. Secondary lung abscess represented 54% of their series, which was much lower compared with our cases (70%). Antibiotics alone resulted in complete recovery with slow resolution of the radiograph. The sole organism isolated was *S. aureus* (mostly from sputum and 1 from pleural fluid).

In Emanuel and Shulman's series [1], pathogens isolated from deep tracheal suction revealed *S. aureus* in 4, *S. pneumoniae* in 1, and *E. corrodens* in 1, while blood culture yielded *S. pneumoniae* in 1. In the report of 45 pediatric lung abscesses by Tan et al [23], pathogens determined from primary abscess were mostly *S. pneumoniae*, anaerobic bacteria, non-typable *H. influenzae* and *S. aureus*, while *P. aeruginosa*, anaerobic bacteria and fungi were most common in secondary lung abscess. Empiric parenteral antibiotics with anti-Gram-positive activity for both penicillinase-producing *S. aureus* and anaerobes are required [1]. However, antibiotics for Gram-negative pathogens [23] as well as a more aggressive and extensive surgical intervention are preferable for immunocompromised patients [24]. Nevertheless, the prognosis of immunocompromised children depends mainly on their underlying processes, and this was also observed in our series. Patients with severe sepsis or poorly-controlled bronchopleural fistula may also need surgical intervention [25].

In our series, the mean duration of antibiotic therapy was 28 days in primary lung abscess and 45 days in secondary lung abscess. Intravenous empiric antibiotics should be used until the patient is stable and no longer infectious (afebrile at least 48 to 72 h). Then, antibiotics may be shifted to oral form for an additional 2-3 weeks, with the total duration of antibiotic therapy being at least 4 weeks [1]. The duration of antibiotic therapy should be tailored individually according to the condition of the patient and the clinical response.

Fatal cases had longer hospitalization and longer parenteral antibiotic therapy than survival cases in this

study (p=0.023 and 0.016, respectively). The size of lung abscess (>4 cm) was not correlated with the mortality rate although patients in the mortality group had larger sizes of lung abscesses. Patients with complicated courses (complication, mortality, or sequelae) were found to need longer oxygen use, to be predominantly male, and to have higher referral and mortality rates in our series (p=0.04, 0.018, 0.034, 0.006, respectively). In the primary lung abscess group, 3 had complications (pneumothorax, respiratory failure, and osteomyelitis) although none had sequelae or mortality. Few pediatric studies have reported factors associated with outcome.

In conclusion, childhood primary lung abscess rarely occurs and 70% of lung abscesses happen in children with underlying medical conditions. Percutaneous aspiration early in the course, especially in those with underlying chronic diseases, will be helpful as a treatment guide, to shorten the admission course, and to decrease the complication and mortality rates. The procedure performed in primary abscess could provide guidance as to the etiology of infection and suitable antibiotic treatment. Both oral anaerobes and *S. aureus* remain the core pathogens, and should be covered empirically in patients with primary lung abscess. Gram-negative pathogens, such as *Pseudomonas* spp., should be considered in those with secondary lung abscess.

References

1. Emanuel B, Shulman ST. Lung abscess in infants and children. Clin Pediatr (Phila) 1995;34:2-6.
2. Pennza PT. Aspiration pneumonia, necrotizing pneumonia, and lung abscess. Emerg Med Clin North Am 1989;7:279-307.
3. Lorenzo RL, Bradford BF, Black J, Smith CD. Lung abscesses in children: diagnostic and therapeutic needle aspiration. Radiology 1985;157:79-80.
4. Lee SK, Morris RF, Cramer B. Percutaneous needle aspiration of neonatal lung abscesses. Pediatr Radiol 1991;21:254-7.
5. Pena Grinan N, Munoz Lucena F, Vargas Romero J, Alfageme Michavila I, Umbria Dominguez S, Florez Alia C. Yield of percutaneous needle lung aspiration in lung abscess. Chest 1990;97:69-74.
6. Yang PC, Luh KT, Lee YC, Chang DB, Yu CJ, Wu HD, et al. Lung abscesses: US examination and US-guided transthoracic aspiration. Radiology 1991;180:171-5.
7. McCracken GH Jr. Lung abscess in childhood. Hosp Pract 1978;13:35-6.
8. Asher MI, Spier S, Beland M, Coates AL, Beaudry PH. Primary lung abscess in childhood: the long-term outcome of conservative management. Am J Dis Child 1982;136:491-4.
9. Bruckheimer E, Dolberg S, Shlesinger Y, Bar Ziv Y, Branski D, Kerem E. Primary lung abscess in infancy. Pediatr Pulmonol 1995;19:188-91.
10. Yen CC, Tang RB, Chen SJ, Chin TW. Pediatric lung abscess: a retrospective review of 23 cases. J Microbiol Immunol Infect 2004;37:45-9.
11. Hill MK, Sanders CV. Anaerobic disease of the lung. Infect Dis Clin North Am 1991;5:453-66.
12. Cuestas RA, Kienzle GD, Armstrong JD 2nd. Percutaneous drainage of lung abscesses in infants. Pediatr Infect Dis J 1989; 8:390-2.
13. Ball WS Jr, Bisset GS 3rd, Towbin RB. Percutaneous drainage of chest abscesses in children. Radiology 1989;171:431-4.
14. Al-Salem AH, Ali EA. Computed tomography-guided percutaneous needle aspiration of lung abscesses in neonates and children. Pediatr Surg Int 1997;12:417-9.
15. Wong KS, Yeow KM, Huang YC, Lin TY. Early echo-guided percutaneous aspiration of peripheral lung abscesses in children: report of two cases. Zhonghua Min Guo Xiao Er Ke Yi Xue Hui Za Zhi 1997;38:145-8.
16. van Sonnenberg E, D'Agostino HB, Casola G, Wittich GR, Varney RR, Harker C. Lung abscess: CT-guided drainage. Radiology 1991;178:347-51.
17. Cowles RA, Lelli JL Jr, Takayasu J, Coran AG. Lung resection in infants and children with pulmonary infections refractory to medical therapy. J Pediatr Surg 2002;37:643-7.
18. Rice TW, Ginsberg RJ, Todd TR. Tube drainage of lung abscesses. Ann Thorac Surg 1987;44:356-9.
19. Brook I, Finegold SM. Bacteriology and therapy of lung abscess in children. J Pediatr 1979;94:10-2.
20. Bartlett JG. Anaerobic bacterial infections of the lung and pleural space. Clin Infect Dis 1993;16 Suppl 4:S248-55.
21. Bartlett JG. Antibiotics in lung abscess. Semin Respir Infect 1991;6:103-11.
22. Hirshberg B, Sklair-Levi M, Nir-Paz R, Ben-Sira L, Krivoruk V, Kramer MR. Factors predicting mortality of patients with lung abscess. Chest 1999;115:746-50.
23. Tan TQ, Seilheimer DK, Kaplan SL. Pediatric lung abscess: clinical management and outcome. Pediatr Infect Dis J 1995; 14:51-5.
24. Tseng YL, Wu MH, Lin MY, Lai WW, Liu CC. Surgery for lung abscess in immunocompetent and immunocompromised children. J Pediatr Surg 2001;36:470-3.
25. Wu MH, Tseng YL, Lin MY, Lai WW. Surgical treatment of pediatric lung abscess. Pediatr Surg Int 1997;12:293-5.